T113
+Y12
3203

YALE UNIVERSITY LIBRARY
3 9002 06584 5506

ULTRASONIC MEASUREMENT OF EARLY FETAL GROWTH

LEONARD HARRIS COHEN

1972

MUDD
LIBRARY
Medical

YALE

MEDICAL LIBRARY

Permission for photocopying or microfilming of "Ultrasonic Measurement of Early Fetal Growth"

(TITLE OF THESIS)

for the purpose of individual scholarly consultation or reference is hereby granted by the author. This permission is not to be interpreted as affecting publication of this work or otherwise placing it in the public domain, and the author reserves all rights of ownership guaranteed under common law protection of unpublished manuscripts.

Leonard H Calen

Signature of Author

5/5/72

Date

ULTRASONIC MEASUREMENT OF EARLY FETAL GROWTH

by
Leonard Harris Cohen
B.A. University of Pennsylvania 1968

Submitted to the Faculty of the
Department of Obstetrics and Gynecology of
Yale University School of Medicine
in partial fulfillment of the requirements for
the degree of Doctor of Medicine

ACKNOWLEDGEMENT

I would like to thank Dr. Stuart Campbell, Queen Charlotte's Hospital, London, for the opportunity to work with him. I would also like to thank Dr. Ernest Kohorn for his sincere interest, guidance, and friendship.

Digitized by the Internet Archive
in 2017 with funding from
Arcadia Fund

https://archive.org/details/ultrasonicmeasur00cohe

TABLE OF CONTENTS

Introduction..page 2

Patients and Methods..page 7

Results and Discussion..page 9

Bibliography..page 28

INTRODUCTION

Donald, MacVicar and Brown (10) first described the use of ultrasonics in obstetrics and gynecology in 1958. Ultrasonic waves are pulsed sound waves of frequency greater than 20,000 cycles per second. These high frequencies and concomitant short wavelength give ultrasound waves a degree of resolution which makes possible their use as a diagnostic tool (19). At these frequencies, sound energy, unlike audible sound energy, can be directed in beam form and can be reflected, refracted, and absorbed. One can therefore plot interfaces which produce echoes. When a beam of ultrasonic waves is directed into the body and meets a tissue interface at right angles, an echo is created which is reflected back to a ceramic crystal mounted in a probe which acts as a transducer as well as receiver. This converts the reflected sound energy into electrical energy which is amplified and displayed on an oscilloscope screen. In the case of obstetrics, the abdomen is coated with olive or mineral oil to insure acoustic coupling. Diagnostic ultrasonics is especially well suited for obstetrics because one is dealing with objects floating in amniotic fluid, the latter being an excellent acoustic medium. It is for this reason that the fetus and placenta can be so well visualized ultrasonically.

The two ultrasonic display systems commonly used are the unidimensional A scan and the Plan Position Indication (PPI) or B scan which gives a two-dimensional picture with outlines of anatomical structures. The B scan is used alone for the visualization of the gestational sac, fetal parts, and uterus prior to the appearance of the fetal head at 13

weeks. In this method a compound sector scanning technique has been developed (10) in which the operator moves the probe linearly across the abdomen while at the same time rocking it through an arc of 60 degrees. This allows the detection of many more interfaces and creates an excellent probability that each interface will be detected and recorded. An echogram of the structure being scanned is produced as the dots of light from each interface coalesce. The echogram is recorded from the oscilloscope screen with a Polaroid camera.

Prior to the development of Campbell's method of fetal cephalometry (3), A scan alone was used to determine the fetal biparietal diameter. With A scan alone, measurements could only be made when the fetal head was palpable. This was difficult in cases of hydramnios and multiple pregnancy and usually impossible before the 26th week of pregnancy. Measurements which could have been of value to the clinician were often not obtainable. Campbell's method, as described below, therefore makes the measurement of biparietal diameters during the second trimester of pregnancy possible. With the improved method, the orientation of the fetal head is first determined by B scan display. This is done by means of two scans, longitudinal and transverse, made at right angles to each other (Figure 1). The longitudinal scan is performed first to determine the amount of rotation of the head about a vertical axis. This helps one to make a transverse scan at an angle at which the two parietal bones are parallel to each other. If this scan were made at the correct angle, then a midline echo running between the parietal echoes should be observed.

Figure 1a.

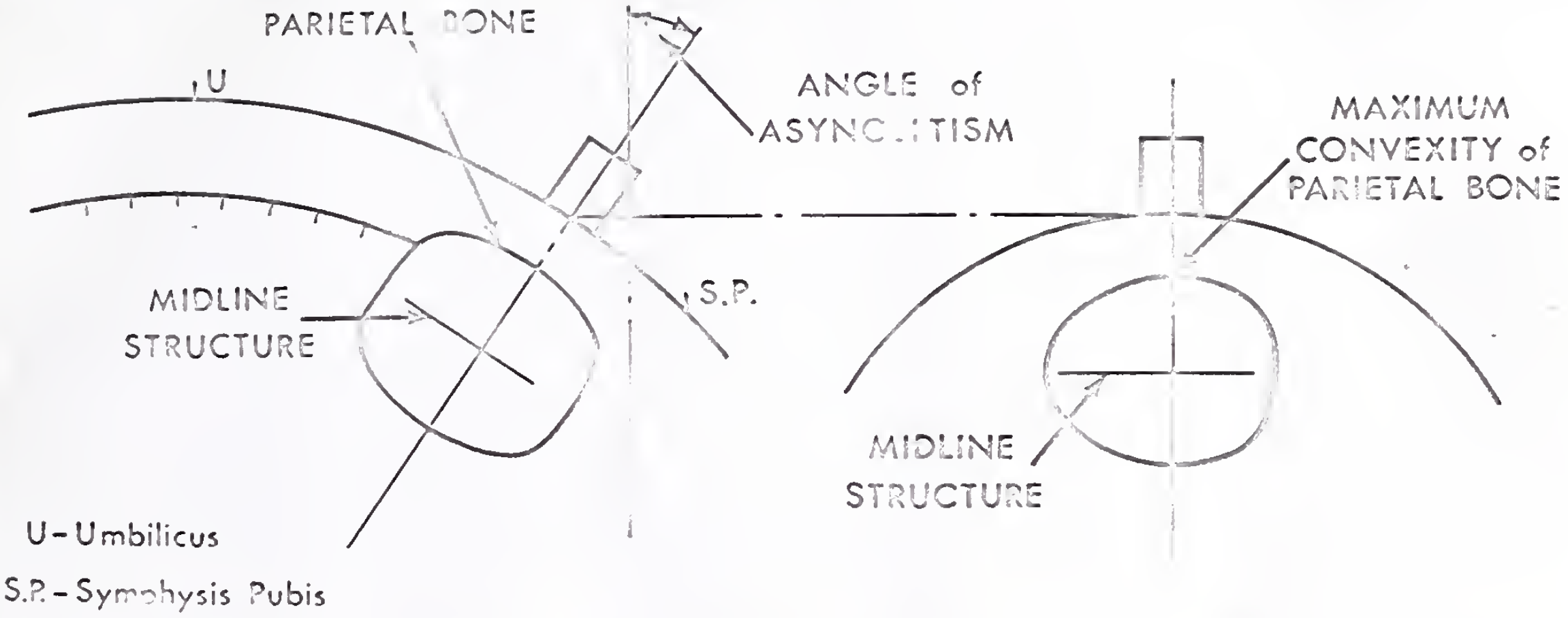
PARIETAL BONE
U
ANGLE of ASYNCLITISM
MAXIMUM CONVEXITY of PARIETAL BONE
S.P.
MIDLINE STRUCTURE
MIDLINE STRUCTURE
U - Umbilicus
S.P. - Symphysis Pubis

Diagrammatic illustration of the scanning method when the vertex is in the occipito-transverse position: (left) longitudinal scan to determine the angle of asynclitism, (right) transverse scan tilted to the angle of asynclitism. The beam is directed along the biparietal diameter.

Figure 1b.

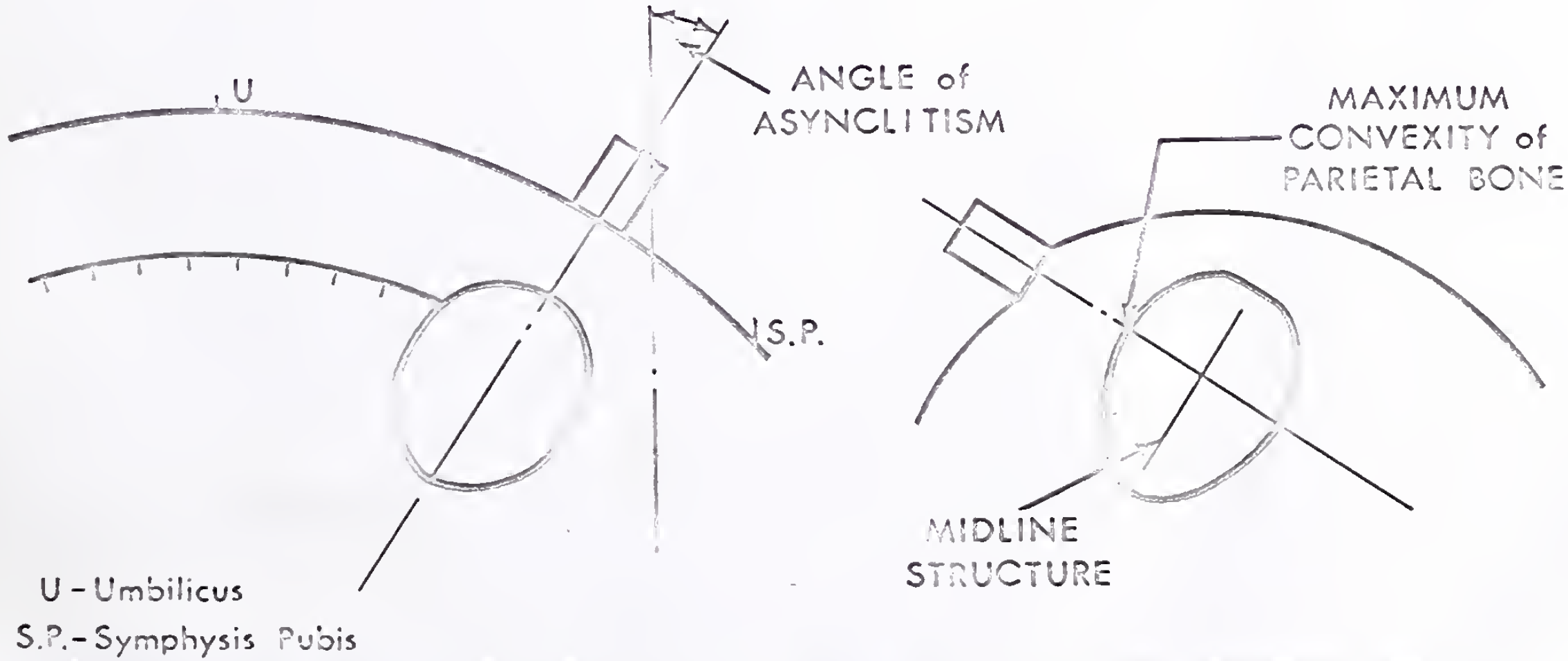
ANGLE of ASYNCLITISM
U
MAXIMUM CONVEXITY of PARIETAL BONE
S.P.
MIDLINE STRUCTURE
U - Umbilicus
S.P.- Symphysis Pubis

In this example the vertex is in the occipito-anterior or occipito-posterior position: (left) longitudinal scan with the beam directed along the occipito-frontal diameter, (right) transverse scan tilted to the angle of asynclitism. The beam is directed along the biparietal diameter.

The most likely source of this echo is thought to be the medial side of each hemisphere (15). One then switches to A scan display and two vertical deflections from the skull bones are produced and a direct reading is made by means of a marker unit.

Ultrasonics can be used to measure intrauterine fetal growth from as early as the fifth week of amennorrhea (8). At this time the early products of conception can normally be visualized in the upper pole of the uterus. A small white ring, representing the gestational sac, may be seen by the sixth week of gestation. The appearance of this ring can sometimes confirm a pregnancy before the urinary gonadotrophin test is positive. Donald (6) has described the loss of the gestational sac as an ultrasonically visualized structure at about the 11th week of amenorrhea. The disappearance of the ring is accounted for by the fusion of the decidua capsularis with the decidua parietalis. This results in the loss of an interface which can reflect ultrasonic waves. Donald (8) has demonstrated an embryonic pole within the gestational sac at nine weeks.

Hellman et al. (13) have measured the rate of growth of the gestational sac from the fifth to the tenth week in three diameters -- the antero-posterior and longitudinal on the longitudinal scan, and a transverse diameter on the transverse scan. This group has also measured uterine size from the fifth to the 20th week and has demonstrated a linear rate of growth of both the uterus and the gestational sac during early pregnancy.

The most difficult period for measuring fetal growth by ultrasounds

is from the 11th to the 13th week(8). One is cast adrift at this time between the disappearance of the gestational sac at 11 weeks and the appearance of the fetal head during the 13th week.

This investigation attempts to establish the accuracy of fetal cephalometry in the second trimester of pregnancy beginning in the 13th week and to construct a fetal growth curve based upon the measurement of biparietal diameters. It will also attempt to document ultrasonic findings prior to the 13th week as parameters of fetal growth and well-being.

An important advantage of ultrasound for diagnostic purposes over other methods for measurement of fetal growth, such as radiologic examination, is its safety. Hellman et al. showed that neither the frequency of ultrasound examination nor the time of the earliest examination appears to increase the incidence of fetal abnormalities and abortion (12). Fetal abnormalities were no more common among 3297 women examined by diagnostic ultrasounds than in the general population. All work using both human and animal tissue has so far failed to show any deleterious effects at energy levels used in diagnostic work.

PATIENTS and METHODS

The apparatus used was the Diasonagraph (Nuclear Enterprises Ltd., Edinburgh, Scotland). This was originally designed by Donald, MacVicar, and Brown (10). The electronic caliper unit was incorporated into the Diasonagraph so that orientation and measurement of the fetal head could be carried out on one display unit. The caliper unit cursors were modified so that they were capable of measuring fetal heads of all sizes. Scans could be performed in any plane at any angle.

Patients in their second trimester of pregnancy who were undergoing hysterotomy for psychiatric reasons were examined at Queen Charlotte's Hospital, London, in order to establish the accuracy of the method and to construct a growth curve for the second trimester of pregnancy. A small group of patients was also examined at Yale-New Haven Hospital. Women not undergoing hysterotomy were also examined. Measurements of biparietal diameters in these cases were used only in the construction of the growth curve, since they could not be used to establish the accuracy of the method.

Three ultrasonic caliper readings were taken as described above to assess the reproducibility of the caliper recordings. The technique of external cephalometry was as follows. A pair of steel calipers was passed over the maximum transcoronal diameter of the fetal skull so that the tips of the arms of the calipers were just in contact with the head without causing indentation. A locking screw on

the caliper prevented any alteration in the position of the arms. The distance between the arms of the caliper was measured with an engineering vernier caliper, thus allowing measurements to the nearest tenth of a millimeter.

Patients less than 13 weeks pregnant were also examined at Queen Charlotte's Hospital. They were examined by B scan in both longitudinal and transverse planes. Polaroid photographs were taken to document findings. It was necessary in these early pregnancies for the patients to have full bladders. The full bladder served to move the uterus into a position where it could better be reached by ultrasounds. In addition, the full bladder served as an excellent medium for the transmission of ultrasonic waves.

A study was also undertaken to substantiate or disprove the statement of Hellman et al. (13) that the head is sometimes round when seen earliest ultrasonically with all diameters being nearly equal. The technique of external cephalometry as described above was used to compare biparietal with occipito-frontal diameters in fetuses from 13 to 20 weeks maturity.

RESULTS and DISCUSSION

Fifty cases were collected to establish the accuracy of the method by this worker and Dr. Stuart Campbell (4). The average standard deviation of three measurements of the biparietal diameter in 50 fetuses was 0.25 mm. by ultrasonic recordings in utero and 0.29 mm. by caliper recordings after delivery. These deviations were small and indicate a high degree of reproducibility. The mean of each of the three recordings was therefore accepted as the true reading.

A comparison of the ultrasonic and caliper readings is summarized in Table I. The mean error was 0.9 mm. and the maximum error 3.7 mm. There is a high degree of positive correlation between the ultrasonic and caliper recordings (Figure 2) and this is highly significant statistically ($r = 0.9944$, $p < 0.001$).

Comparison with Campbell's previous study (3) of 35 fetuses delivered by Caesarean section (Table II) shows a close similarity in the distribution of errors.

In this worker's series of 16 cases, the results (Figure 3, Table III), while too few to be statistically significant, are similar to the results of the study done with Dr. Campbell in terms of mean error, maximum error, and distribution of error (Table IV).

Thirty cases were collected by this worker to construct a fetal growth curve of the second trimester of pregnancy based upon biparietal diameter measurements. These results are shown in Figure 4

Table I

Case no.	Maturity (weeks)	Ultrasonic Measurement (mm.)	Caliper Measurement (mm.)	Discrepancy (mm.)
1	13	19.4	21.0	-1.6
2	13	22.9	22.6	+0.3
3	14	27.9	26.1	+1.8
4	14	28.0	27.9	+0.1
5	14	28.2	27.9	+0.3
6	14	28.6	28.3	+0.3
7	14	29.6	28.4	+1.2
8	15	33.6	33.1	+0.5
9	15	34.0	33.5	+0.5
10	15	34.2	34.0	+0.2
11	16	34.9	35.5	-0.6
12	16	35.1	34.8	+0.3
13	17	36.5	37.5	-1.0
14	17	36.7	36.8	-0.1
15	16	37.1	38.6	-1.5
16	16	37.2	39.5	-2.3
17	17	37.9	38.4	-0.5
18	17	41.7	39.6	+2.1
19	18	43.6	47.3	-3.7
20	17	44.2	44.1	+0.1
21	17	44.6	45.8	-1.2
22	18	44.6	44.2	+0.4
23	18	45.4	44.9	+0.5
24	18	45.6	46.0	-0.4
25	19	45.9	46.7	-0.8
26	18	46.4	45.8	+0.6
27	19	46.7	46.6	+0.1
28	21	49.2	50.6	-1.4
29	20	49.5	47.1	+2.4
30	20	49.5	49.4	+0.1
31	20	49.9	51.2	-1.3
32	20	50.8	49.0	+1.8
33	20	51.1	49.7	+1.4
34	21	51.3	52.8	-1.5
35	20	51.8	53.0	-1.2
36	20	51.8	53.3	-1.5
37	21	52.1	52.7	-0.6
38	21	53.8	54.1	-0.3
39	21	54.6	53.3	+1.3
40	21	54.7	54.3	+0.4
41	22	55.1	55.4	-0.3
42	21	55.6	55.2	+0.4
43	22	56.8	59.4	-2.6
44	22	57.7	59.0	-1.3
45	23	58.8	59.3	-0.5
46	23	60.0	60.6	-0.6
47	23	60.2	60.6	-0.4
48	23	61.4	61.6	-0.2
49	24	62.2	63.6	-1.4
50	23	62.3	61.9	+0.4

Figure 2

Hysterotomy Study (Campbell and Cohen)

Ultrasonic V. Caliper Measurement

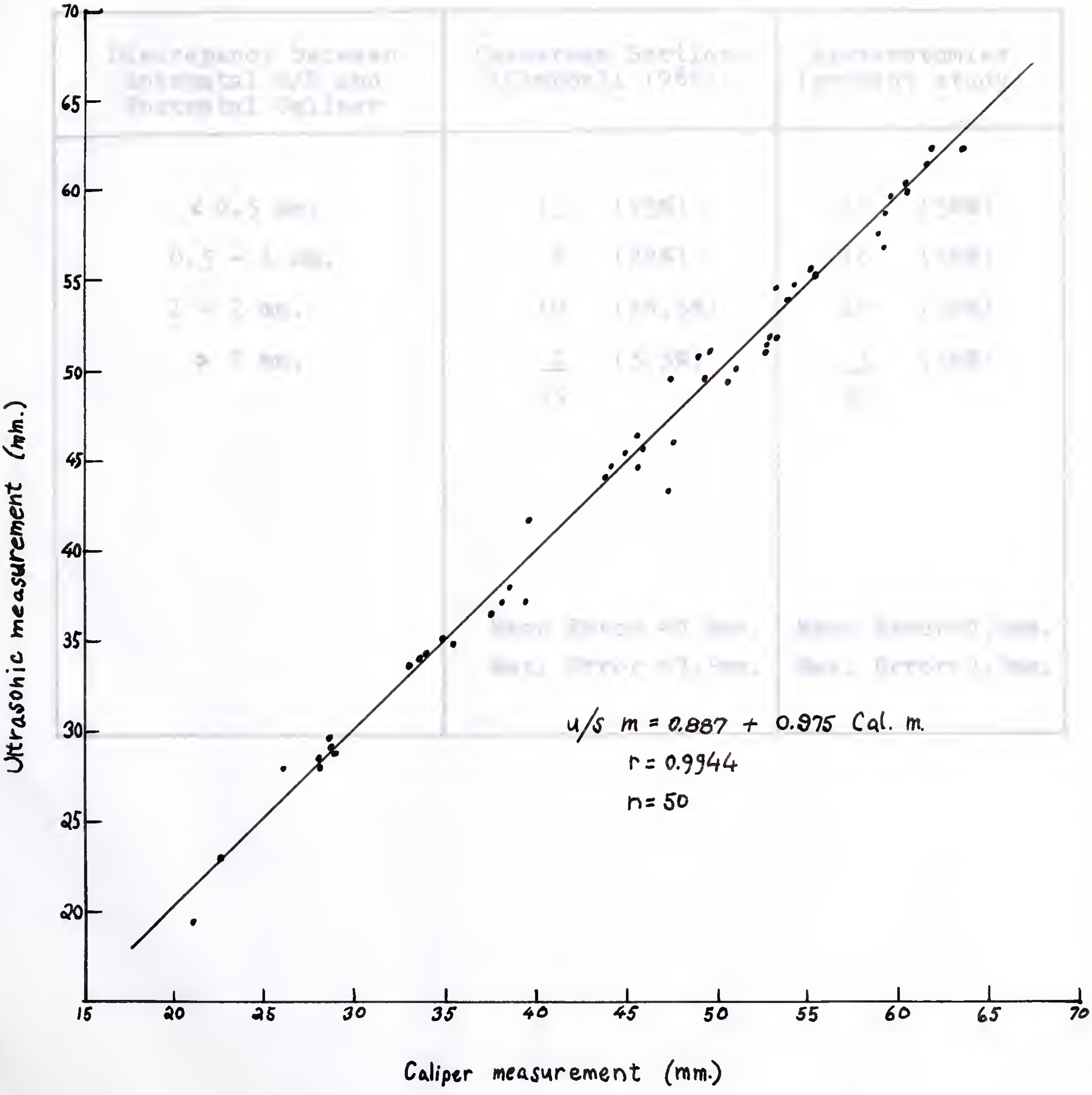

$u/s\ m = 0.887 + 0.975$ Cal. m.

$r = 0.9944$

$n = 50$

Table II

Discrepancy between Antenatal U/S and Postnatal Caliper	Caesarean Sections (Campbell 1968)	Hysterotomies (present study)
< 0.5 mm.	15 (43%)	19 (38%)
0.5 - 1 mm.	8 (23%)	10 (20%)
1 - 2 mm.	10 (28.5%)	16 (32%)
> 2 mm.	2 (5.5%)	5 (10%)
	35	50
	Mean Error =0.8mm. Max. Error =3.5mm.	Mean Error=0.9mm. Max. Error=3.7mm.

Figure 3

Hysterotomy Study (Cohen)

Ultrasonic v. Caliper Measurement

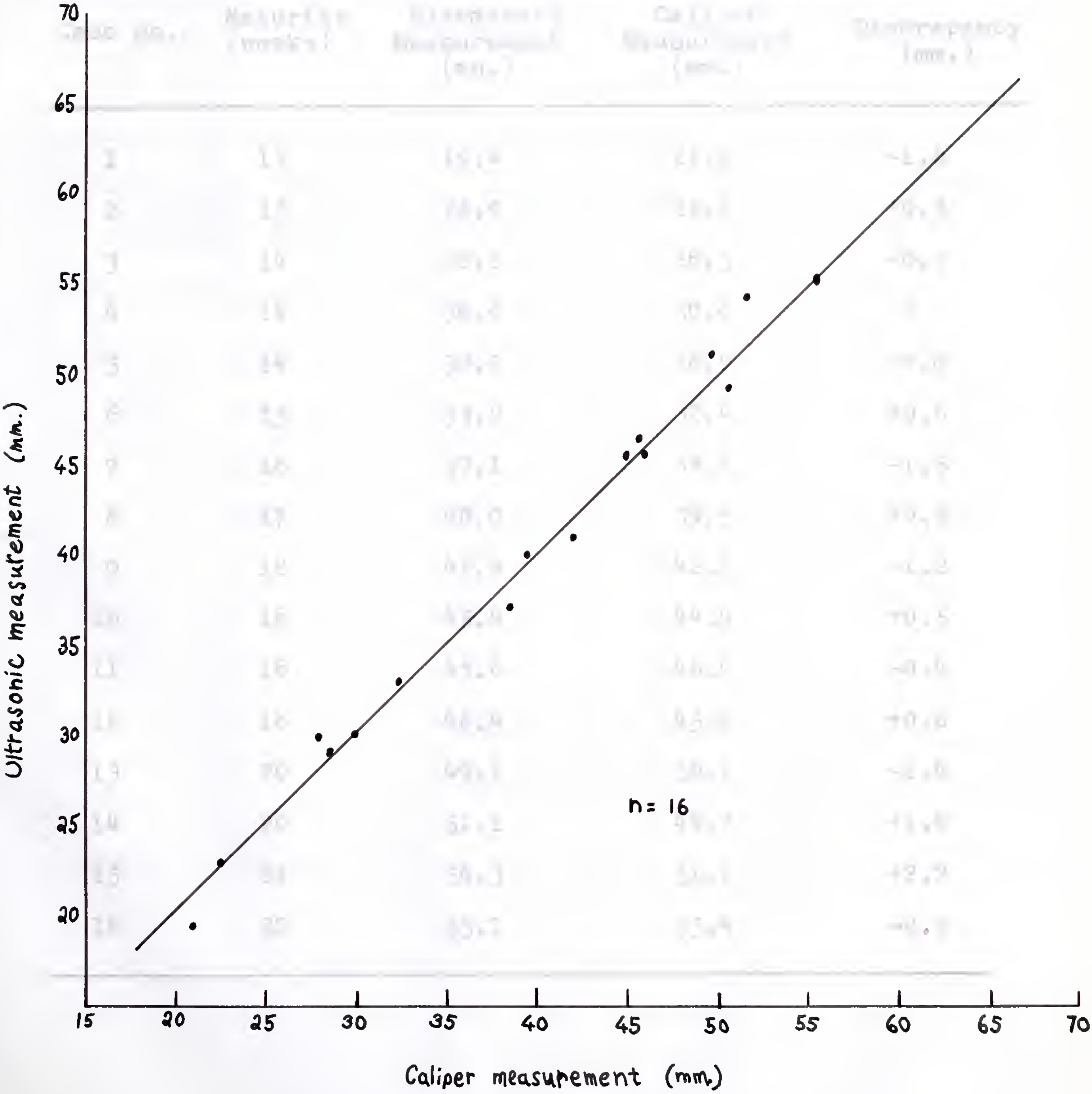

Table III

Case no.	Maturity (weeks)	Ultrasonic Measurement (mm.)	Caliper Measurement (mm.)	Discrepancy (mm.)
1	13	19.4	21.0	-1.6
2	13	22.9	22.6	+0.3
3	14	28.6	28.3	+0.3
4	14	30.0	30.0	0
5	14	30.0	28.0	+2.0
6	15	33.0	32.4	+0.6
7	16	37.1	38.6	-1.5
8	17	40.0	39.5	+0.5
9	18	41.0	42.2	-1.2
10	18	45.4	44.9	+0.5
11	18	45.6	46.0	-0.4
12	18	46.4	45.8	+0.6
13	20	49.2	50.6	-1.4
14	20	51.1	49.7	+1.4
15	21	54.3	51.6	+2.7
16	22	55.1	55.4	-0.3

Table IV

Discrepancy between Antenatal U/S and Postnatal Caliper	Hysterotomies (Campbell & Cohen)		Hysterotomies (Cohen)	
< 0.5 mm.	19	(38%)	5	(31%)
0.5 - 1 mm.	10	(20%)	4	(25%)
1 - 2 mm.	16	(32%)	6	(37%)
> 2 mm.	5	(10%)	1	(6%)
	50		16	
	Mean Error=0.9mm.		Mean Error=1.0mm.	
	Max. Error=3.7mm.		Max. Error=2.7mm.	

and Table V. The biparietal diameter increased an average of 3.9 mm. per week from the 13th to the 20th week. This compares with an average growth rate per week of 2.8 mm. from the 20th to the 30th week and 1.7 mm. from the 30th to the 40th week of gestation (5).

In 12 fetuses measured by caliper between 10 and 20 weeks gestational age (Table VI), it was found that the occipito-frontal diameter was on the average 21 per cent greater than the biparietal diameter. This disagrees with the claim of Hellman et al. (13) that the head is circular in the early weeks of gestation. If the occipito-frontal diameter were measured instead of the biparietal diameter, it would result in an error of one week in the estimation of maturity at 14 weeks gestation and of four weeks at 20 weeks gestation.

Figures 5-8 show compound B and A scan tracings showing measurements of fetal heads at 14,16,18, and 19 weeks, respectively. The midline echoes are clearly demonstrated with both compound B and A scan techniques.

The study was also able to document ultrasonic findings similar to those described by other workers prior to 13 weeks. The gestation sac was visualized as early as six weeks (Figure 9). This is consistent with the earliest findings of Donald (6). Figure 10 demonstrates a nine week uterus. In it can be visualized the gestation sac, within which fetal parts can be seen. Because the same patient was examined again eight weeks later, the second examination should have been consistent with a 17 week gestation if the initial impression of a nine week uterus was correct. The biparietal diameter

Figure 4

Growth Curve
for
12-23 Weeks Gestation

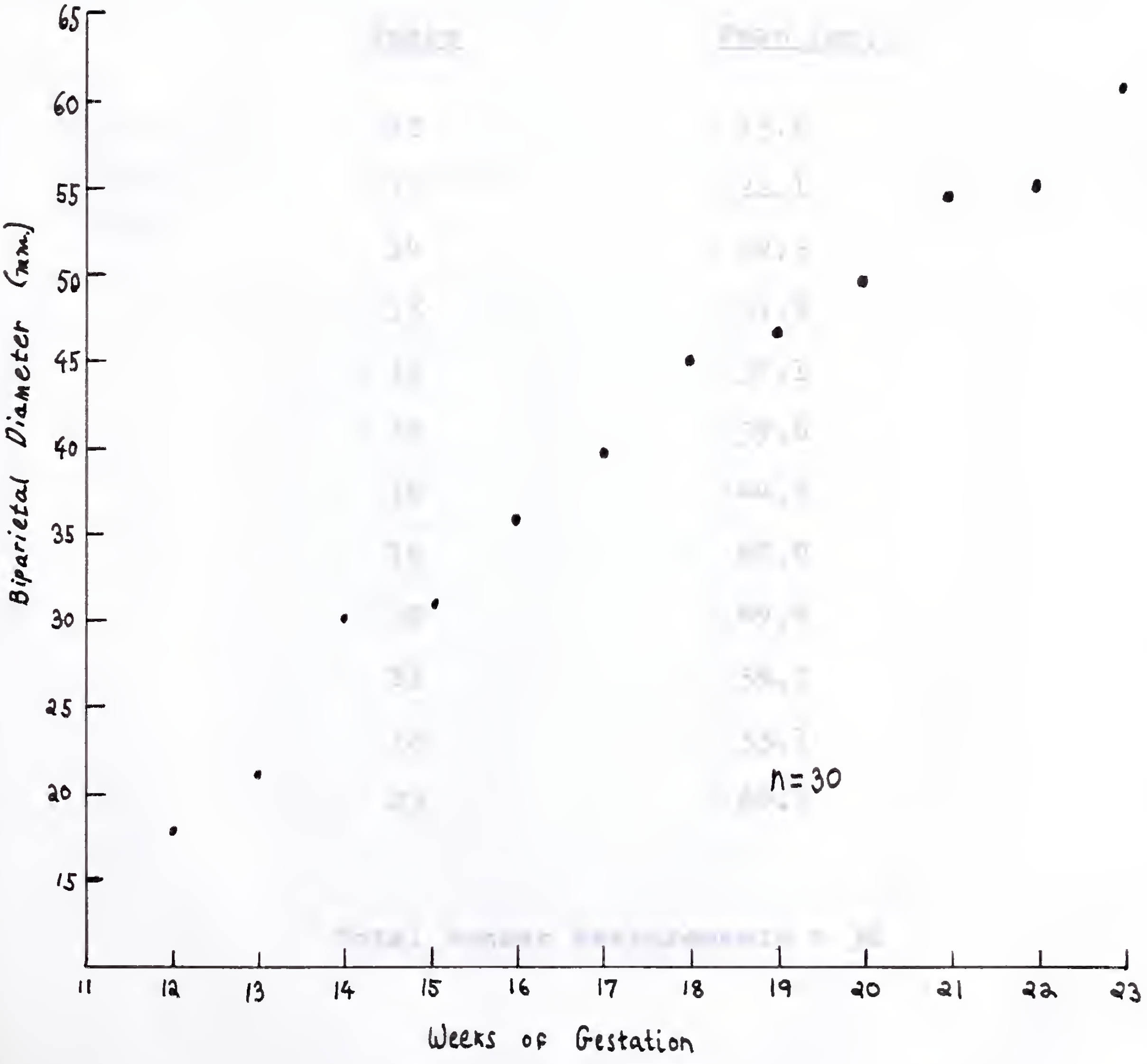

Table V

Growth Curve Mean Weekly Measurements

Weeks	Mean (mm.)
12	15.6
13	22.1
14	29.5
15	31.9
16	37.1
17	39.0
18	44.5
19	47.0
20	49.4
21	54.3
22	55.1
23	60.7

Total Number Measurements = 30

Table VI

Comparison between Biparietal Diameter and Occipito-Frontal Diameter in 12 Fetuses

Biparietal diameter (mm.)	Occipito-frontal diameter (mm.)	Difference (mm.)	Percentage increase	Maturity (weeks)
21.0	24.0	3.0	14	13
22.6	26.5	3.9	17	13
25.5	31.0	5.5	22	13
28.3	33.5	5.2	18	14
28.3	34.7	6.4	23	14
32.4	36.4	4.0	13	15
38.6	48.3	9.7	25	16
42.2	50.9	8.7	21	18
44.9	58.0	13.1	29	18
45.8	56.1	10.3	24	18
46.0	54.2	8.2	18	18
50.6	66.2	15.6	30	20

Figure 5
(left) Compound B scan tracing of a fetal head at 14 weeks maturity. The midline echo is clearly demonstrated. (right) A scan tracing of the same head showing the cephalic echoes and midline echo on the horizontal time base.

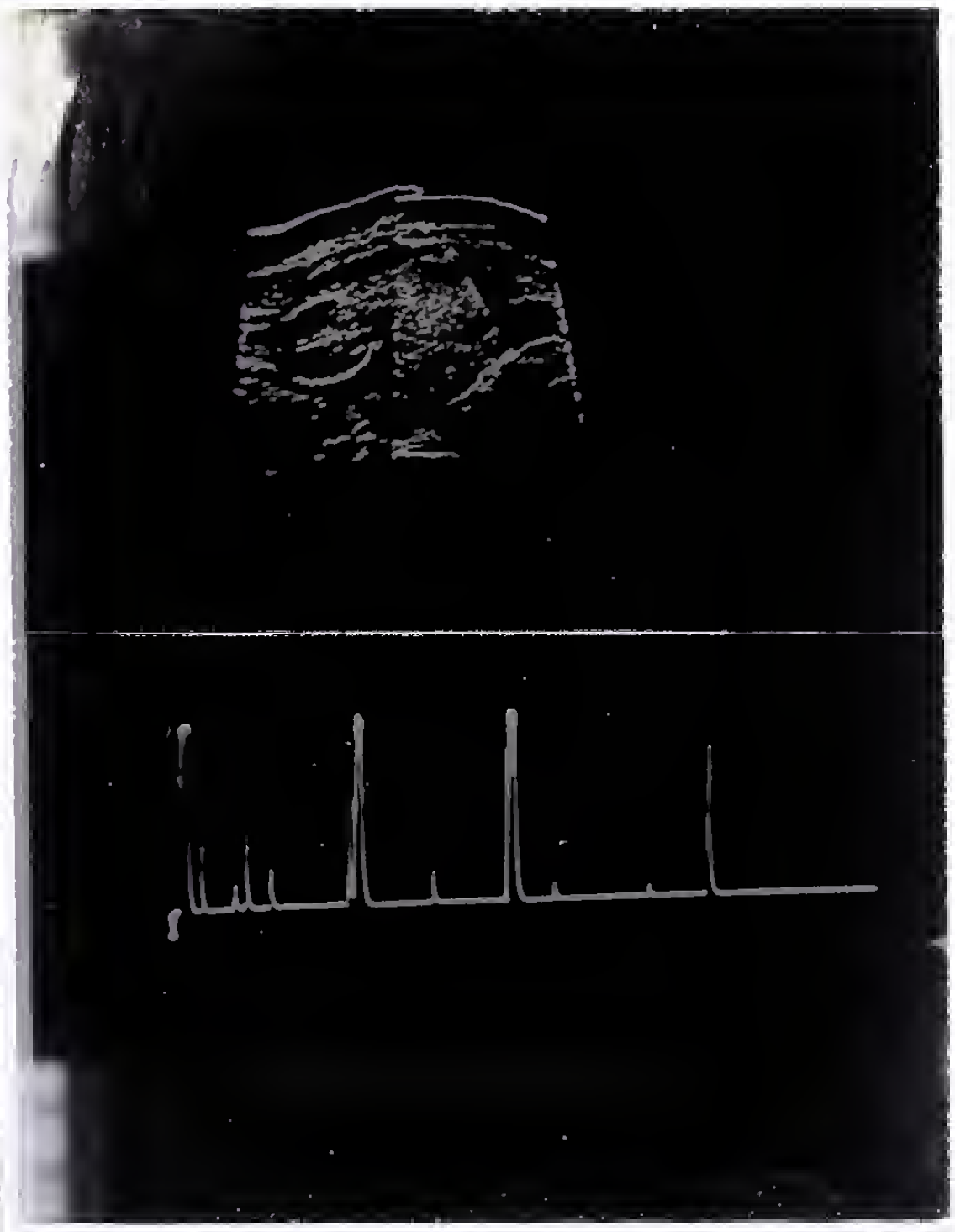

Figure 6
Compound B and A scan tracings showing measurement of a fetal head at 16 weeks maturity.

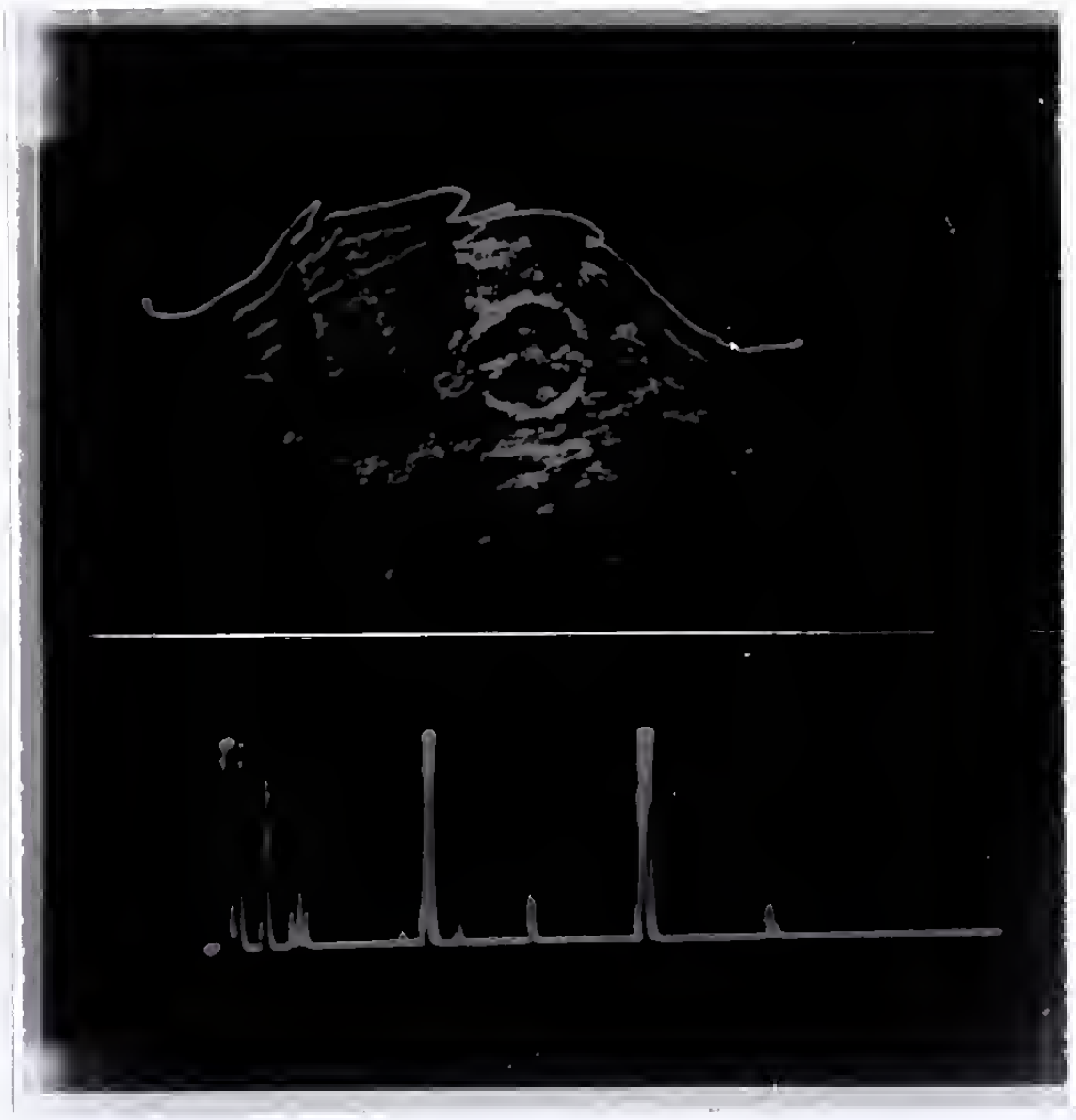

Figure 7
Compound B and A scan tracings showing measurement of a fetal head at 18 weeks maturity.



Figure 8
Compound B and A scan tracings showing measurement of a fetal head at 19 weeks maturity.

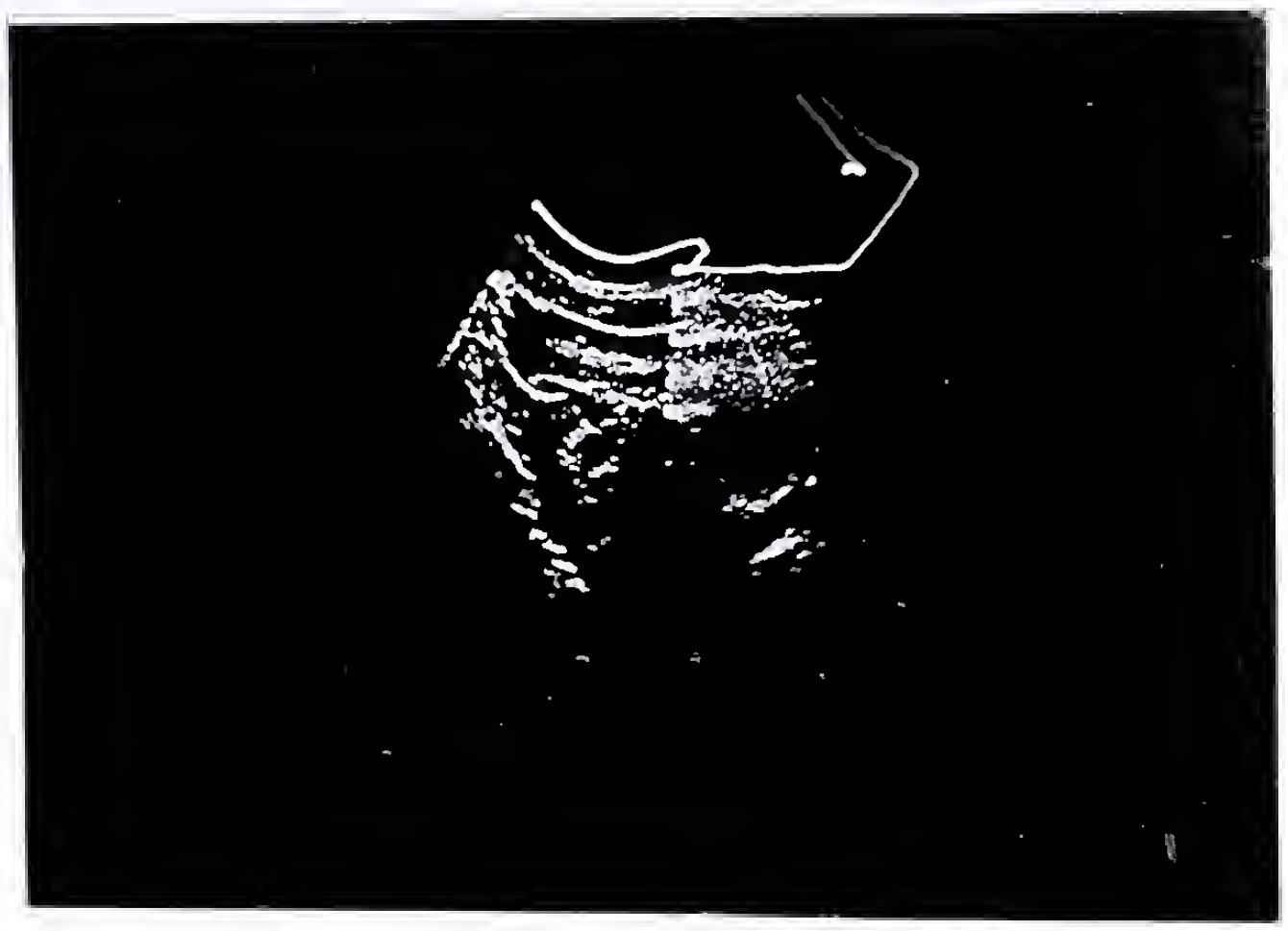

Figure 9
Gestation sac within uterine cavity seen as characteristic white ring at six weeks gestation.

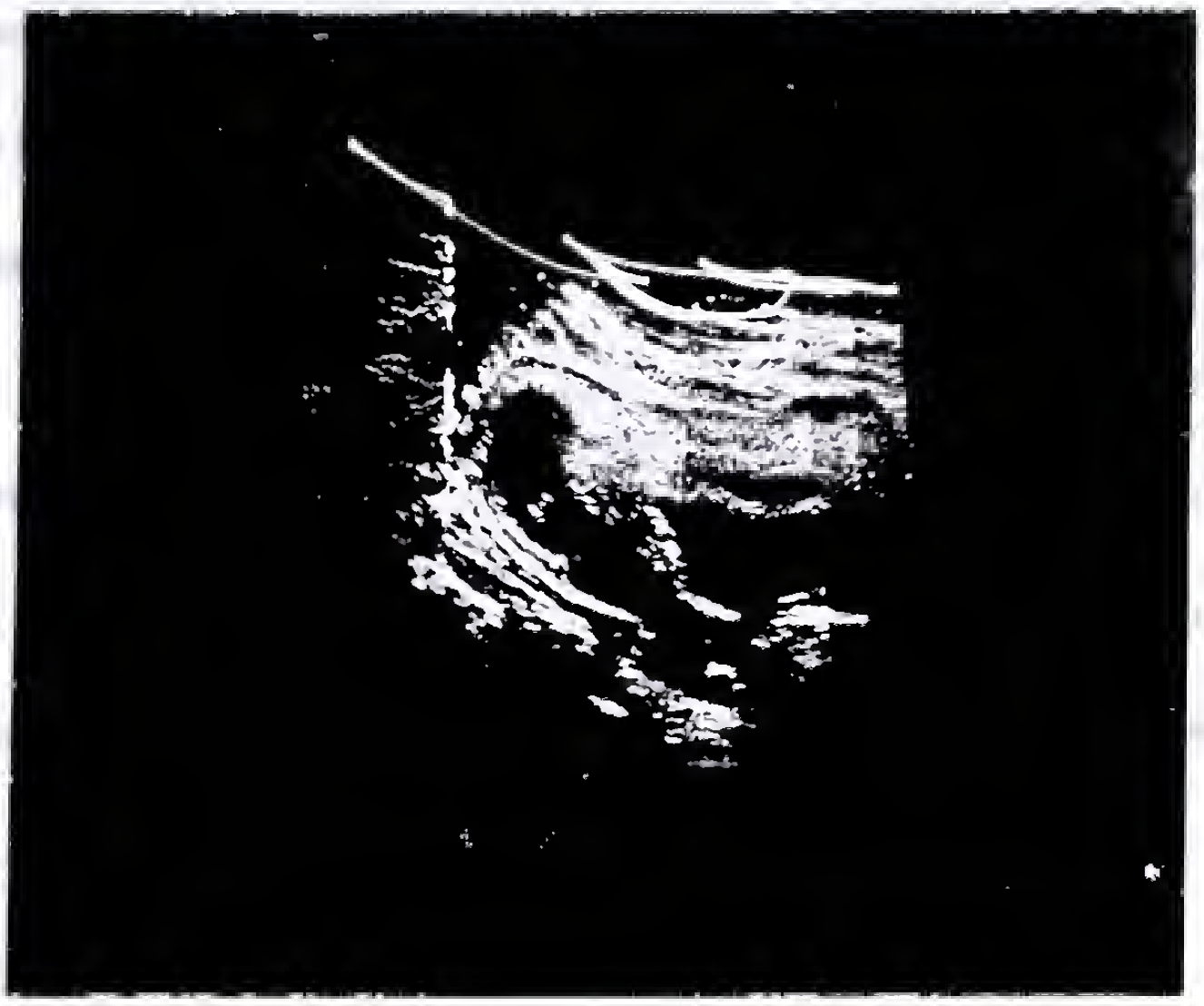

Figure 10
Fetal parts seen within gestation sac at nine weeks maturity. Drawing below shows same case with structures labelled.



B = bladder
G = gestation sac
F = fetal parts
U = uterus
C = cervix

of the head at that time was, in fact, 39.7 mm., consistent with a 17 week gestation.

Fetal parts are better seen in a gestation sac scanned at 11 weeks of amenorrhea.(Figure11). When this patient was reexamined six weeks later at 17 weeks maturity, a biparietal diameter of 37.4 mm. was recorded. These two examples show a good correlation between gestational age assessed by measuring the size of the gestational sac and subsequent measurement of the biparietal diameter after 13 weeks. This demonstrates that a good assessment of fetal age can be obtained during the first trimester.

On two occassions it was possible to measure fetal heads at 12 weeks menstrual age in patients certain of their dates. In one case the biparietal diameter was 16 mm. and in the other 15.6 mm. (Figure 12). Since they were not hysterotomy patients, it was not possible to confirm these findings by direct caliper measurement. These findings are consistent with average biparietal diameters of 21.1 mm. measured at 13 weeks of gestation if one considers that the growth increment from 13 to 14 weeks is 6.2 mm. and would be expected to be nearly the same for the period from 12 to 13 weeks. No mention is made in the literature of ultrasonic measurement of so small a biparietal diameter.

This study has shown the accuracy that can be achieved in measuring the fetal head from the 13th week of gestation onwards with combined A and B scan tracings. The establishment of a growth

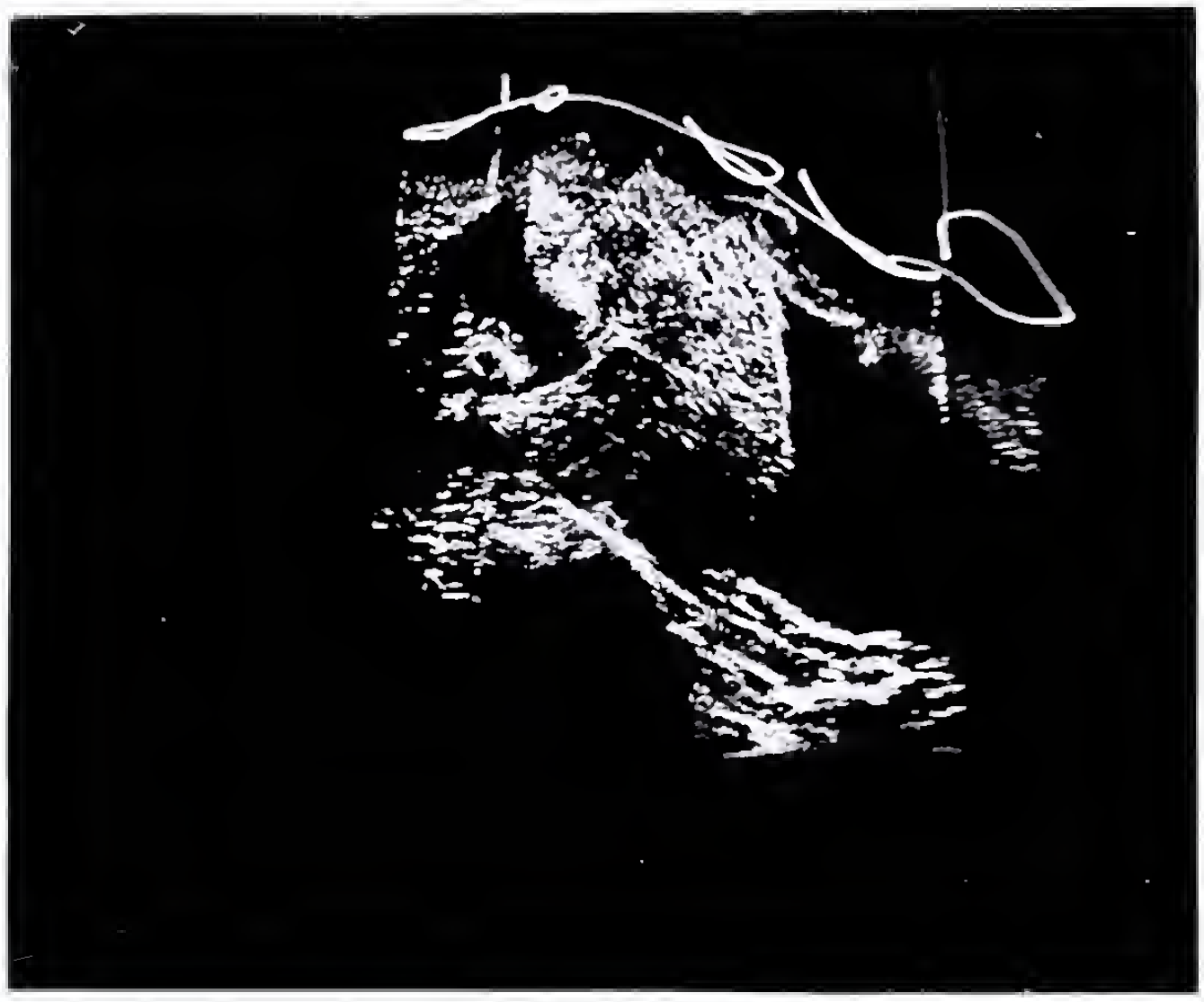

Figure 11
Fetal parts easily visualized within gestation sac at 11 weeks maturity.

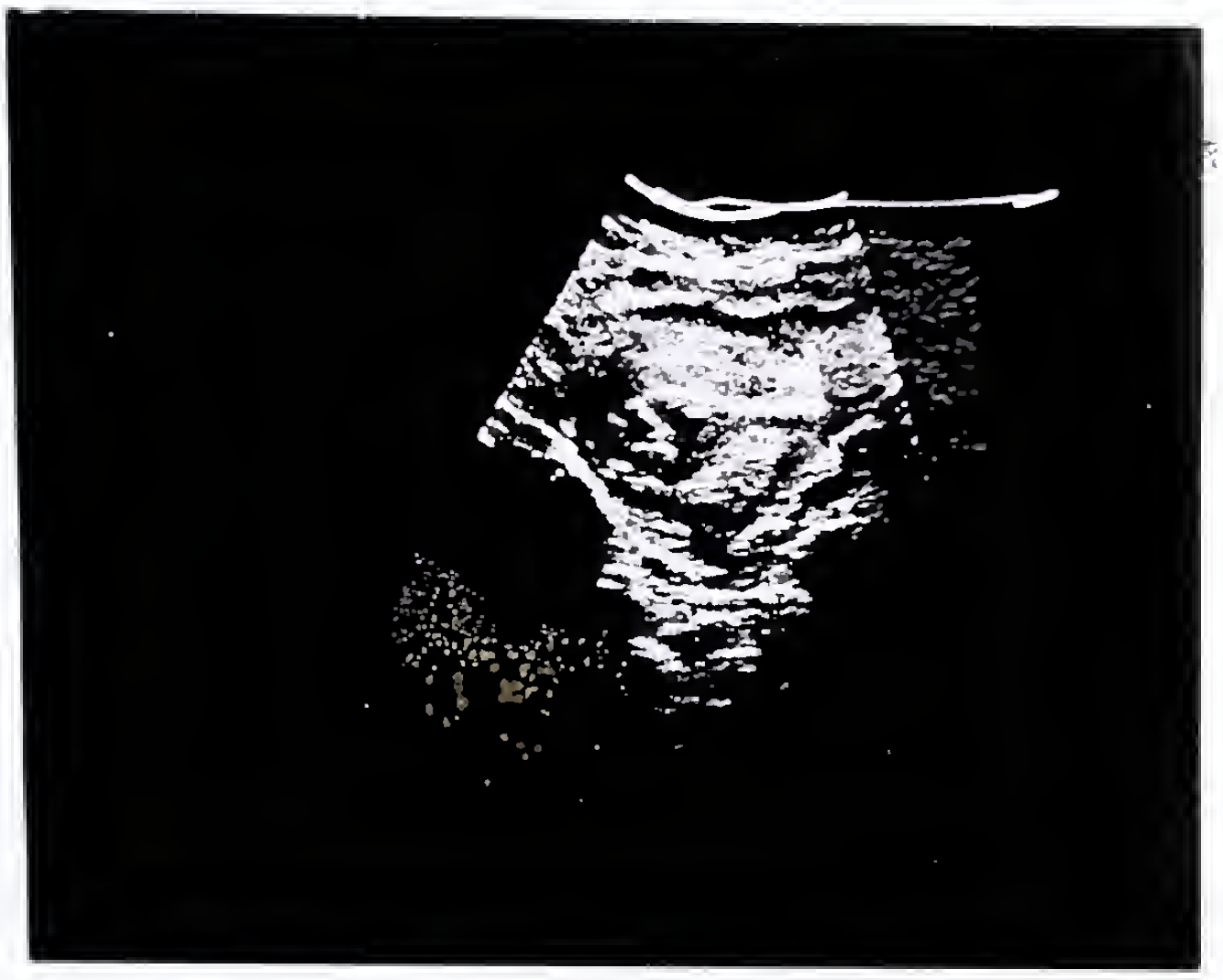

Figure 12
B scan showing fetal head at twelve weeks maturity, with portion of midline echo visualized. Biparietal diameter was 15.6 mm.

curve for normal pregnancy based upon biparietal diameters from the 13th week onward is a useful addition to the parameters available for measuring prenatal development.

Other techniques for assessing growth are generally unavailable or of limited usefulness before the 20th week of gestation. One method is to use the pattern of urinary excretion of estriol as an index of fetal welfare during pregnancy. These determinations have been made as early as 16 weeks of pregnancy (22), but are of limited clinical value before the final trimester. Placental lactogenic hormone level is another parameter for assessing fetal growth and well being. Levels of this hormone have been determined as early as six weeks gestation (18), but its clinical value actually is found later in pregnancy. The measurement of alkaline phosphatase is also more suited for assessment of more advanced pregnancies. Although used only in the final trimester of pregnancy, determination of amniotic fluid creatinine and bilirubin concentrations and percentage of fetal sebaceous cells is mentioned here for completeness.

Willocks et al. (20) have shown that the growth rate of the biparietal diameter was a useful aid in the assessment of cases of suspected dysmaturity, being most useful when measurements were started as early in pregnancy as possible and frequent measurements were made. In their series, cephalometry was not performed prior to the 24th week of pregnancy. With the growth curve for the second trimester available, however, they would have been able to begin

cephalometry more than ten weeks earlier and to determine sooner and more accurately which cases were likely to develop placental insufficiency. This would be of use to patients who have hypertension, pre-eclampsia, diabetes mellitus, chronic nephritis, recurrent antepartum hemorrhage, or severe cardiac disease as a result of which placental insufficiency might occur. The determination of dates by ultrasonic cephalometry is important in deciding when to induce labor with postmaturity.

The corroboration of ultrasonic findings prior to the 13th week demonstrates the reproducibility of this relatively new diagnostic science. It is more difficult to evaluate an early fetus by ultrasound than later on in pregnancy, but with the aid of the patient's full bladder and some patience, it is consistently possible.

It is interesting that fetal cephalometry was first done with A scan alone. Although A scan was used in this study, biparietal diameters were measured consistently with B scan caliper unit cursors. It would be worthwhile to perform a study comparing the accuracy of combined A and B scanning versus compound B scanning alone. If, as one might suspect, the compound B technique alone is as accurate as the combined method, then A scan would become unnecessary as a routine part of fetal cephalometry. The savings in time gained from this would be magnified as fetal cephalometry grows in popularity and becomes a more established component of obstetrical diagnosis.

BIBLIOGRAPHY

1. Brown, B., and Gordon, D., *Ultrasonic Techniques in Biology and Medicine*, Illiffe Books Ltd., London, 1967.
2. Brown, T.G., Direct contact ultrasonic scanning techniques for the visualization of abdominal masses, Proceedings of the Second International Conference on Medical Electronics, Paris, June 1959.
3. Campbell, S., An improved method of fetal cephalometry by ultrasound, Journal of Obstetrics and Gynaecology of the British Commonwealth, 75:568, 1968.
4. Campbell, S., Ultrasonic fetal cephalometry during the second trimester of pregnancy, Journal of Obstetrics and Gynaecology of the British Commonwealth, 77:1057, 1970.
5. Campbell, S., Proceedings of the 14th Annual Scientific Congress of the American Institute of Ultrasound in Medicine, 1970.
6. Donald, I., Transcripts of the College of Physicians, Surgeons and Gynaecologists of South Africa, 11:61, 1967.
7. Donald, I., On launching a new diagnostic science, American Journal of Obstetrics and Gynecology, 103:609, 1969.
8. Donald, I., Sonar as a method of studying prenatal development, Journal of Pediatrics, 75:326, 1969.
9. Donald, I., Ultrasonics in diagnosis (sonar), Proceedings of the Royal Society of Medicine, 62:22, 1969.

10. Donald, I., MacVicar, J., and Brown, T.G., Investigation of abdominal masses by pulsed ultrasound, Lancet, 1:1188, 1958.

11. Gordon, D., Ultrasound as a Diagnostic and Surgical Tool, E & S Livingstone Ltd., Edinburgh, 1964.

12. Hellman, L.M., Duffus, G.M., Donald, I., and Sundén, B., Safety of diagnostic ultrasound in obstetrics, Lancet, 1:1133, 1970.

13. Hellman, L.M., Kobayashi, M., Fillisti, L., and Lavenhar, M., The growth and development of the human fetus prior to the twentieth week of gestation, American Journal of Obstetrics and Gynecology, 103:789, 1969.

14. Klopper, A., The assessment of feto-placental function by estriol assay (review), Obstetrical and Gynecological Survey, 23:813, 1968.

15. Kohorn, E.I., An evaluation of ultrasonic fetal cephalometry, American Journal of Obstetrics and Gynecology, 97:553, 1967.

16. Kohorn, E.I., Pritchard, J.W., and Hobbins, J.C., The safety of clinical ultrasonic examination, Obstetrics and Gynecology, 29:272, 1967.

17. MacLeod, S.C., Brown, J.B., Beisher, N.A., and Smith, M.A., The value of urinary oestriol measurements during pregnancy, Australian and New Zealand Journal of Obstetrics and Gynaecology, 7:25, 1967.

18. Saxena, B.N., Refetoff, S., Emerson Jr., K., and Selenkow, H.A., A rapid radioimmunoassay for human placental lactogen, American Journal of Obstetrics and Gynecology, 101:874, 1968.

19. Thompson, H.E., The clinical use of pulsed echo ultrasound in obstetrics and gynecology, Obstetrical and Gynecological Survey, 23:903, 1968.

20. Willocks, J., Donald, I., Campbell, S., and Dunsmore, I.R., Intrauterine growth assessed by ultrasonic foetal cephalometry, Journal of Obstetrics and Gynaecology of the British Commonwealth, 74:639, 1967.

YALE MEDICAL LIBRARY

Manuscript Theses

Unpublished theses submitted for the Master's and Doctor's degrees and deposited in the Yale Medical Library are to be used only with due regard to the rights of the authors. Bibliographical references may be noted, but passages must not be copied without permission of the authors, and without proper credit being given in subsequent written or published work.

This thesis by has been used by the following persons, whose signatures attest their acceptance of the above restrictions.

NAME AND ADDRESS		DATE
Steven Warsof	545 Ellsworth Ave, New Have	1/29/76